European Bison Conservation Newsletter Vol 7 (2014) pp: 19–28

Clostridium perfringens type A infection in European bison (*Bison bonasus*) – case report

Vladimir Petrov[1], I. Kalkanov[2], G. Zhelev[1], P. Marutsov[1], K. Koev[1], G. Mihaylov[1], N. Groseva[2]

[1] Department of Microbiology, Infection and Parasitic Diseases, Faculty of Veterinary Medicine, Trakia University, Stara Zagora, Bulgaria
[2] Department of General and Clinical Pathology, Faculty of Veterinary Medicine, Trakia University, Stara Zagora, Bulgaria

Abstract: A clinical case of *Clostridium perfringens* type A infection in European bison (*Bison bonasus*) is described. Clinical, autopsy, histological and bacteriological examinations were carried out. A *Clostridium perfringens* strain was isolated from intestinal content. Gross and microscopic lesions were described in detail. The disease was characterized with anorexia, abdominal pain, tachypnea, scanty stool, depression, dehydration and melena. General anatomy findings consisted in catarrhal haemorrhagic inflammation of the abomasum, excessive ballooning of intestines, haemorrhages in intestines, peritoneum, pleura, diaphragm, spleen and kidney. The liver and kidneys were dystrophic. Histopathologically, severe granular and fatty dystrophy of liver and kidney cells, as well as dystrophic and necrobiotic changes mainly in small intestine mucosa, the abomasum and fore stomachs were detected.

Key words: *Bison bonasus, Clostridium perfringens,* enterotoxaemia

Introduction

Clostridium perfringens is probably the commonest bacterial pathogen, and the most important agent causing intestinal clostridial infections in domestic animals. Some types (mainly type A) are isolated both from intestinal content and the environment, whereas others (types B, C, D, E) inhabit mainly animal intestines (Songer 1996). *C. perfringens* type A produces mainly α toxin, but in pigs with necrotic enteritis and cattle with haemorrhagic bowel syndrome, β2 toxin-producing strains were also identified (Gibert *et al*. 1997). Alpha toxin is a multifunctional phospholipase with haemolytic, necrotising and lethal properties. It hydrolyses membrane lipids of erythrocytes, thrombocytes, leukocytes, endothelial, muscle cells etc., leading to lysis or other forms of cytotoxicity (Smith 1979).

By the end of the 20th and the beginning of the 21st century, the reports about haemorrhagic bowel syndrome in high-yielding lactating cows became more frequent (Cantor 1999; Kirkpatrick 2001; Dennison *et al*. 2002; Midla 2002). Now it is assumed that the main causative agents of this disease are *Clostridium perfringens* type A and *Aspergillus fumigatus* (Godden *et al*. 2001; Dennison *et al*. 2002).

All clostridial enteric infections require predisposing factors resulting in slowdown of bowel content release such as feeding upon frosted or frozen grass forages, sudden transition from dry rough feeds to grazing on pasture especially in early spring, drinking a lot of cold water in winter etc. In cattle, Berghaus *et al.* (2002) have identified as main causes of this phenomenon – feeding high-protein and high-energy diet with low fibre content, rearing in tie-stall barns and therefore, strongly restricted locomotion, breed predisposition with higher prevalence in Holstein-Friesian cattle.

Every disturbance of intestinal tract motility in ruminants leads to retention of bowel content, putrefaction events and proliferation of bacteria which have so far been rapidly released to the large intestine. These conditions cause rapid replication of clostridia in the small intestine, and production of exotoxins that are absorbed through the intestinal wall. Finally, a severe exotoxaemia occurs, accompanied by local mucous coat lesions and general damage of various tissues and organs of affected animal.

Case history

In October 27, 2013, four female and one male European bison, 1.5–2.5 years old, weighing about 250–300 kg, were imported to Bulgaria. The animals were born and reared in Germany on pasture and fed exclusively fresh meadow grass. The bison were transported with a specially designed cargo vehicle. During transportation, the animals received food, water and rests. The travel lasted 3 days. After their arrival in Bulgaria, the European bison were housed in an adaptation centre in the East Rhodope mountains. They were fed meadow hay, alfalfa hay and root vegetables. Three days after their arrival the weather conditions in the region have sharply changed – it started to rain, the temperature dropped to about 10°C. On November 5, 2013, one of females refused to eat, became apathetic, kept itself separate from the other animals, and exhibited tachypnea. The animal was separated from the others, it remained lying and could not stand up. It was treated with intramuscular application of a preparation containing penicillin/streptomycin, by intravenous infusion of 5% glucose and polivitamins. The body temperature of the animal was then 38°C. Few hours after treatment the animal died. Meanwhile, another two females showed similar symptoms. Only one of them had diarrhoea. The faeces were of dark-brown, almost black colour. On November 7, 2013 this animal died too. The carcass of the first bison was subject to necropsy and diagnosis at the Clinical Diagnostic Block of the Faculty of Veterinary Medicine, Trakia University, Stara Zagora. From the second bison, only viscera were sent for general anatomy, histopathological and microbiological examinations.

The necropsy was carried out in the Department of General and Clinical Pathology and microbiological studies – in diagnostics lab of the Department of Veterinary

Microbiology, Infectious and Parasitic Diseases, at the Faculty of Veterinary Medicine, Trakia University, Stara Zagora, Bulgaria.

Material and methods

General anatomy study:

Initially, an exterior check was performed, followed afterwards by inspection of the subcutaneous connective tissue, abdominal and thoracic organs. The routine protocol of autopsy was used.

Histological examination:

Samples from parenchymal organs, alimentary tract and muscles were collected.

Samples for histological examination were fixed in 10% neutral formalin and embedded in paraffin using the routine method with ascending alcohol series. The material was cut on a microtome Leica RM 2235, with cut thickness of 3 μm. The histological sections were stained with haematoxylin-eosin.

Microbiological examination:

Samples from parenchymal organs (lung, liver, spleen, kidney) cardiac blood and ligated small intestine segment were used for microbiological study.

Imprint preparations were initially prepared, stained by Gram, then seen under oil-immersion light microscopy at a magnification of 1000×.

Inoculations were done on blood agar with 7% sheep red blood cells, McConkey agar, tryptic soy broth, selenite broth and incubated at 37°C over 24 h under aerobic conditions. For isolation of anaerobes, blood-sugar (Zeisler) agar and fluid thioglycolate medium (Difco Laboratories) were inoculated and incubated over 48 h at 37°C under anaerobic conditions. For the semi-solid medium, anaerobic conditions were achieved by pouring of sterile liquid paraffin in tubes, and for solid media, Anaero-Pack supplemented with palladium catalyst was used. After 24-hour incubation on the thioglycolate medium, smears and inoculations on blood-sugar Zeisler agar were performed. The staining and cultivation of samples was as described above. The identification of isolates was done by routine microbiological techniques (Quinn *et al.* 1994).

Results

The *post mortem* examination revealed the following gross changes in organs. The external check showed yellowish discharge from the nostrils. The colour and the surface of the buccal and nasal mucous coats were not altered. The conjunctivae were hyperaemic, without discharge. After removal of the skin, the subcutaneous connective tissue were haemorrhagically imbibed. Haemorrhages on trunk muscles (Fig. 1) and haemorrhagic lymphadenitis of superficial lymph nodes were observed.

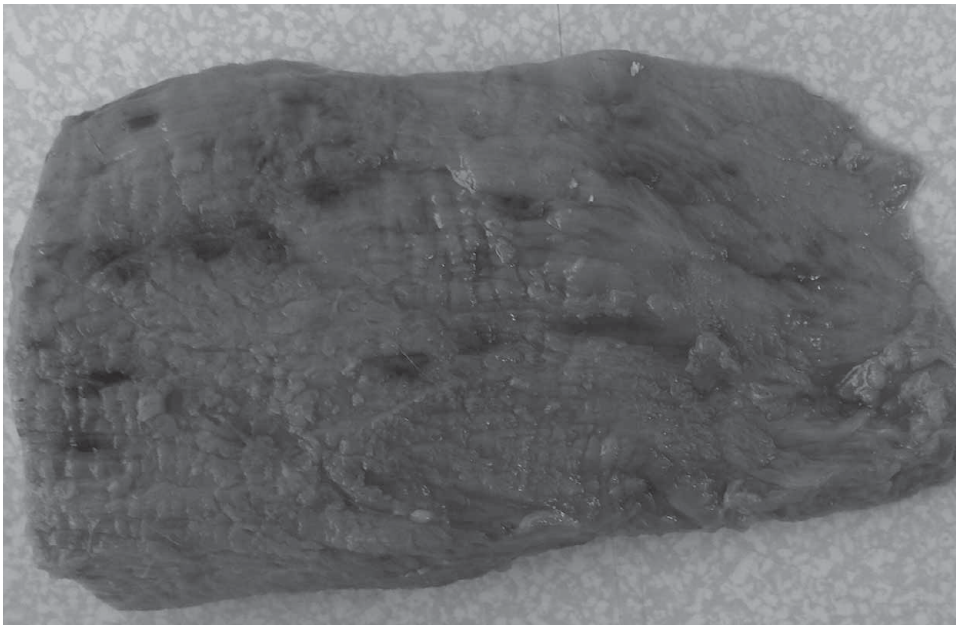

Fig. 1. Haemorrhages on trunk muscles.

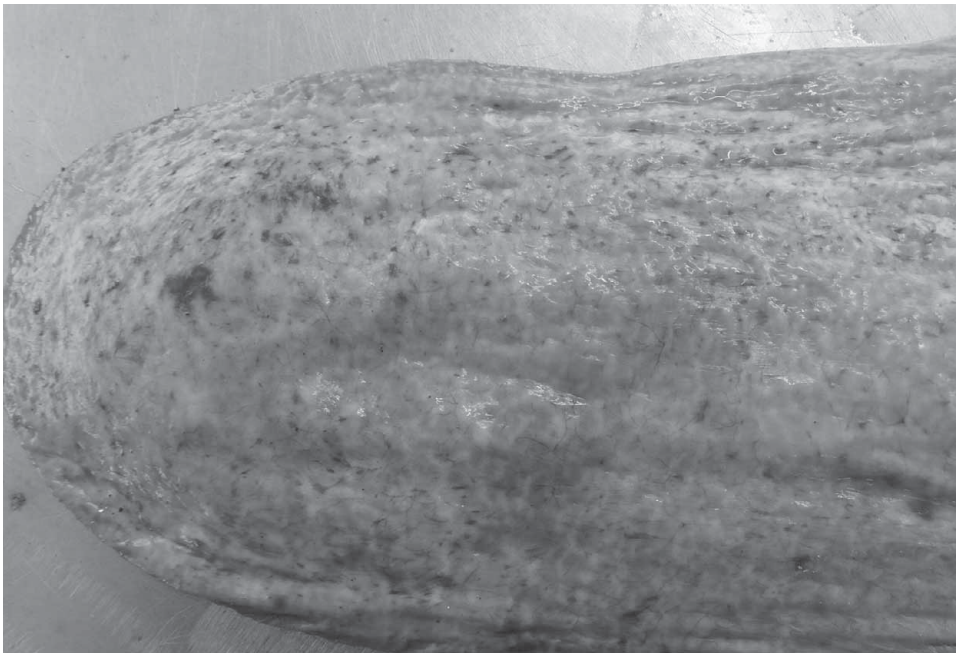

Fig. 2. Spleen – subcapsular petechiae.

After incision of the abdominal cavity, markedly ballooned intestines, haemorrhages on the peritoneum and the diaphragm muscle were seen. The topography of organs was unchanged. The spleen was not enlarged, but subcapsular petechiae were visible (Fig. 2). The liver was of clay-yellowish colour and frail consistence. Kidneys were soft, dark-red, with subcapsular haemorrhages. Haemorrhages of various size were observed on the epicardium and endocardium.

The gross inspection of fore stomachs revealed catarrhal haemorrhagic inflammation of the abomasums (Fig. 3), and hyperkeratotic reticulum mucosa. In the intestinal tract, haemorrhagic enterocolitis with local intestinal wall haemorrhages visible through the serous coat could be observed (Fig. 4).



Fig. 3. Catarrhal haemorrhagic inflammation of the abomasum.

Fig. 4. Small intestines – catarrhal haemorrhagic enterocolitis.

The histological examination of the liver demonstrated severe granular and fatty dystrophy, with necrosis of liver parenchyma at some areas. Multiple haemorrhages were seen (Fig. 5).

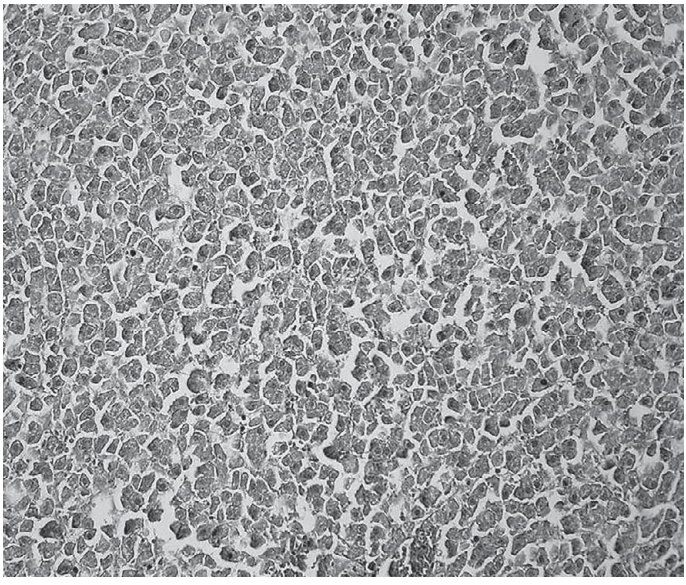

Fig. 5. Liver – granular and fatty dystrophy, with necrosis of parenchyma and multiple haemorrhages.

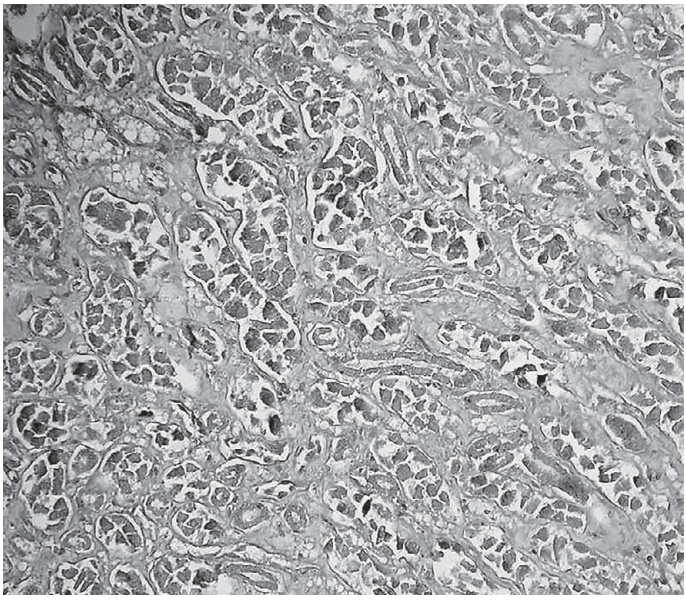

Fig. 6. Kidney – disintegration and desquamation of epithelial cells of proximals tubules.

The kidneys exhibited severe granular dystrophy, desquamation and disintegration of epithelial cells and interstitial haemorrhages.

The histology of the alimentary tract showed dystrophic necrobiotic changes mainly in the mucous coats of the small intestine, the abomasum and fore stomachs. The submucosa was excessively oedematous, blood vessels – hyperaemic, and vast haemorrhages and mononuclear proliferations were detected at some areas.

The findings in the spleen consisted in strong hyperaemia and haemorrhages. Lymph follicles showed rarefaction of specific cells and increase in siderocytes.

The myocardium and skeletal muscles were characterised with strong vascular hyperaemia, and some muscle fibres exhibited cloudy swelling and granular dystrophy.

The microscopic analysis of imprint preparations from parenchymal organs and heart blood did not reveal the presence of any bacterial cells.

The microscopic analysis of imprint preparations from various sections of small intestine showed numerous Gram-positive, large, coarse rods, 1.5–4.5 μm of size. Some bacteria had central or subterminal endospores.

Culturing did not reveal the presence of microbial pathogens in parenchymal organs or heart blood.

After 24-hour incubation on the semi-solid (thioglycolate) medium, multiple gas bubbles were seen under the liquid paraffin layer. Microscopy of smears after 48-hour incubation showed microbial cells with the specific features of the *Clostridium* genus (see above).

Under anaerobic conditions, a pure culture of gray-white haemolytic colonies, 1 to 2 mm in diameter was observed on blood sugar Zeisler agar. On the smears from colonies, the above described clostridial cells were shown.

The biochemical identification revealed the microorganisms belonging to the *Clostridium* genus, and after toxin production typing – to *Clostridium perfringens* type A.

Discussion

The underlying mechanisms of enterotoxaemia in sheep are changes in intestinal motility and slowdown of small intestinal content movement. The emptying of intestinal content is inhibited, and subsequently resident microflora imbalance (dysbiosis) could occur. Clostridia are replicated mainly in the small intestine, where produced microbial exotoxins are rapidly absorbed and spread through lympho-haematogenous route, resulting in progressing general toxaemia. The main predisposing factors are associated with feed and nutrition. Enterotoxaemia is particularly common after grazing on frosted pastures or drinking ice-cold water, intake of spoiled or moulded feed, overfeeding, abrupt change in nutrition, etc. The continuous exposure to various stress factors such as sudden change of the place of living, transportation at long distances, regrouping, change of farm employees,

could result in reduced systemic resistance of the host and clinical manifestation of patient-determined diseases.

A similar theory about the pathogenesis of haemorrhagic bowel syndrome in cows is suggested by Godden *et al*. (2001). They hypothesised that one of the probable causes for the clinical manifestation of the disease is the rapid replication of clostridiae on the background of slower evacuation of intestinal content and intake of high-carbohydrate and high-protein rations. In such cases, the members of the genus *Clostridium* replicate rapidly, produce toxins which are absorbed and thus, responsible for the clinical signs and pathoanatomical and histopathological findings.

In the presented case of *Clostridium perfringens* type A infection in European bison, the simultaneous effects of several predisposing factors are accumulated – transportation stress, sudden change of the habitat and loss of the rest of the herd. All these causes, taken together, have resulted in replication of clostridiae in the intestinal tract and clinical manifestation of *Clostridium perfringens* type A infection.

Similar findings related to a high level of stress on the incidence of haemorrhagic bowel syndrome in cows are reported by Abutarbush and Radostits (2005). The average age of affected animals (4 years on the average) in their study is comparable to that of studied E. bison.

The clinical signs in cows, described by several research teams (Dennison *et al*. 2002; Abutarbush, Radostits 2005) agree with anorexia, abdominal pain, tachypnea, scanty stool, depression, dehydration and melena. In our study, we have not observed the reported decline in milk secretion.

The gross lesions reported in our study are largely similar to those described in high-yielding dairy cows with haemorrhagic bowel syndrome, whose etiology is also attributed to *Clostridium perfringens* type A. The pathoanatomical examination of E. bison revealed small intestinal ballooning, haemorrhagic enteritis and local haemorrhages in the intestinal wall. Similar findings were described by other authors for cows with haemorrhagic bowel syndrome (Cantor 1999; Abutarbush and Radostits 2005). In addition, we established catarrhal haemorrhagic inflammation of the abomasum and hyperkeratotic mucosa of the reticulum. Unlike the findings of Cantor (1999), Godden *et al*. (2001), Kirkpatrick *et al*. (2001), Dennison *et al*. (2002), Abutarbush and Radostits (2005) examined E. bison did not exhibit dark purple-red intestinal areas of varying length as described by Abutarbush and Radostits (2005).

It is acknowledged that *Clostridium perfringens* type A produces several different toxins (alpha, beta and enterotoxin) (Gyles, Thoen 1993; Quinn *et al*. 1994). The alpha toxin is the primary deadly toxin possessing haemolytic and necrotising properties, while the beta toxin is responsible for bowel inflammation and mucosal damage (Carter, Chengappa 1991). The enterotoxin acts on the intestinal mucosa, mainly in the jejunum and the ileum, provoking a severe diarrhea (Gyles, Thoen 1993). Therefore, the observed gross and microscopic changes in the intestines

could be explained by the effect of toxins produced by the *Clostridium perfringens* isolate. The toxaemia was also the cause of observed dystrophic changes in the liver and kidneys, haemorrhages on the peritoneum, costal pleura, diaphragm muscle, spleen and kidneys.

To our best knowledge, there are no data describing intestinal clostridial infections in European bison. The epidemiological data, autopsy and histological results, as well as bacteriological findings allowed assuming that the cause for the described post-transportation mortality case of E. bison was enterotoxaemia induced by *Clostridium perfringens*.

References

Abutarbush S.M., Radostits O.M., 2005. Jejunal hemorrhage syndrome in dairy and beef cattle: 11 cases (2001 to 2003). Can Vet J 46 (8): 711–715.

Berghaus R.D., McCluskey B.J., Callan R.J., 2005. Risk factors associated with hemorrhagic bowel syndrome in dairy cattle. JAVMA 226 (10): 1700–1706.

Cantor G.., 1999. Jejunal hemorrhage syndrome: a new, emerging disease of dairy cows. Washington State Vet Med Assoc Newslett. Jul.

Carter G.R., Chengappa M.M., 1991. Essentials of veterinary bacteriology and mycology. 4th ed. Philadelphia: Lea & Febiger pp. 133–140.

Dennison A.C., VanMetre D.C., Callan R.J., Dinsmore P., Mason G.L., 2002. Hemorrhagic bowel syndrome in dairy cattle: 22 cases (1997–2000). JAVMA 221 (5): 686–689.

Gibert M., Jolivet-Renaud C., Popoff M.R., 1997. Beta2 toxin, a novel toxin produced by *Clostridium perfringens*. Gene, 203 (1): 65–73.

Godden S., Frank R., Ames T., 2001. Survey of Minnesota dairy veterinarians on the occurrence of and potential risk factors for jejunal hemorrhage syndrome in adult dairy cows. The Bovine Practitioner 35: 97–103.

Gyles C.L., Thoen C.O., 1993. Pathogenesis of bacterial infections in animals, 2nd ed. Ames: Iowa State Univ pp. 114–123.

Kirkpatrick M.A., Timms L.L., Kersting K.W., Kinyon J.M., 2001. Case report – jejunal hemorrhage syndrome of dairy cattle. Bovine Practitioner 35: 104–116.

Midla L.T., 2002. Jejunal Hemorrhage Syndrome. In *Tri-State Dairy Nutrition Conference*, Vol. 414: 67–71.

Quinn P.J., Carter M.E., Markey B., Carter G.R., 1994. Clinical Veterinary Microbiology. 1st ed. London: Mosby, 191–208.

Smith L.D., 1979. Virulence factors of Clostridium perfringens. Review of Infectious Diseases 1 (2): 254–262.

Songer J.G., 1996. Clostridial enteric diseases of domestic animals. Clinical microbiology reviews, 9 (2): 216–234.

Infekcja *Clostridium perfringens* typu A u żubra (*Bison bonasus*) – studium przypadku

Streszczenie: W pracy opisany jest kliniczny przypadek infekcji *Clostridium perfringens* typu A u żubra *(Bison bonasus*). Przeprowadzono badanie kliniczne, autopsję, ocenę histologiczną i bakteriologiczną żubrów. Wyizolowano szczep *Clostridium perfringens* z treści jelit. Ogólne i mikroskopowe zmiany zostały opisane. Choroba charakteryzowała się brakiem apetytu, bólem brzucha, przyspieszonym oddechem, skąpym i smolistym stolcem, depresją i odwodnieniem. Ogólne badanie wskazywało na krwotoczne zapalenie trawieńca, wzdęcia i krwotoki w jelitach, otrzewnej, opłucnej, przeponie, śledzionie i nerkach. Histologicznie stwierdzano poważne zmiany dystroficzne wątroby i nerek, jak również nekrotyczne zmiany w błonie śluzowej jelita cienkiego, trawieńca i przedżołądków.